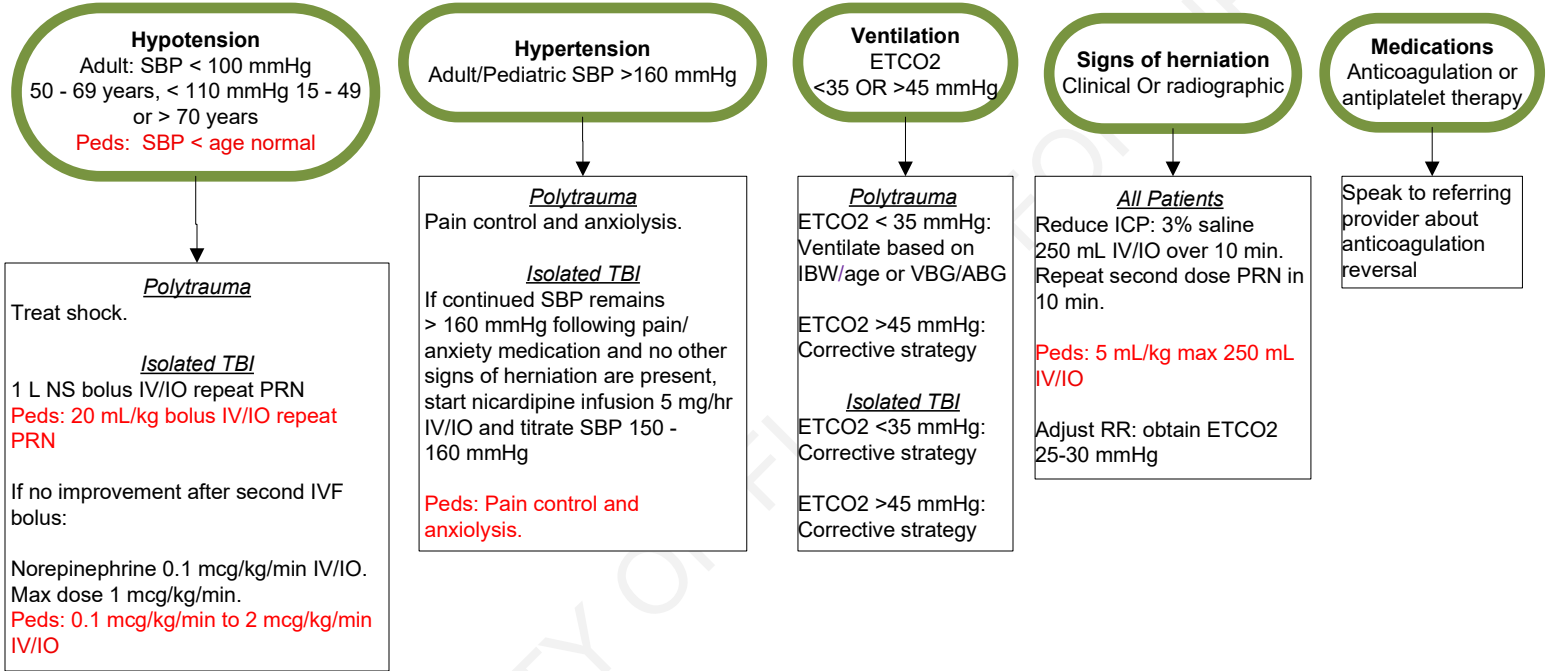




Traumatic Brain Injury



- All Patients**
- Head of bed 30 degrees
 - Continuous ETCO2 monitoring
 - In polytrauma patients, ETCO2 may severely underestimate PaCO2

- Signs of Herniation**
- Clinical signs
- Bradycardia with hypertension
 - GCS < 9 and/or rapid decline of GCS by > 2
 - Dilated and unresponsive pupils
 - Unilateral dilated pupil
 - Extensor posturing
- Radiographic signs
- Herniation, or signs of impending herniation, such as midline shift, mass effect, or cerebral edema, reported

This guideline does not substitute for sound clinical judgment.

DocuSigned by: Approved by: _____ Nick Lehouillier, RN, Chief Flight Nurse	Signed by: Signed by: _____ William B. Weir, MD, Medical Director
--	---

Reviewed 7/9/25 Revised 7/9/25 Posted 9/23/25 Standards and Practice Committee

References:
 Guidelines for the Management of Severe Traumatic Brain Injury, Fourth Edition, 2017
https://journals.lww.com/neurosurgery/fulltext/2017/01000/guidelines_for_the_management_of_severe_traumatic.3.aspx